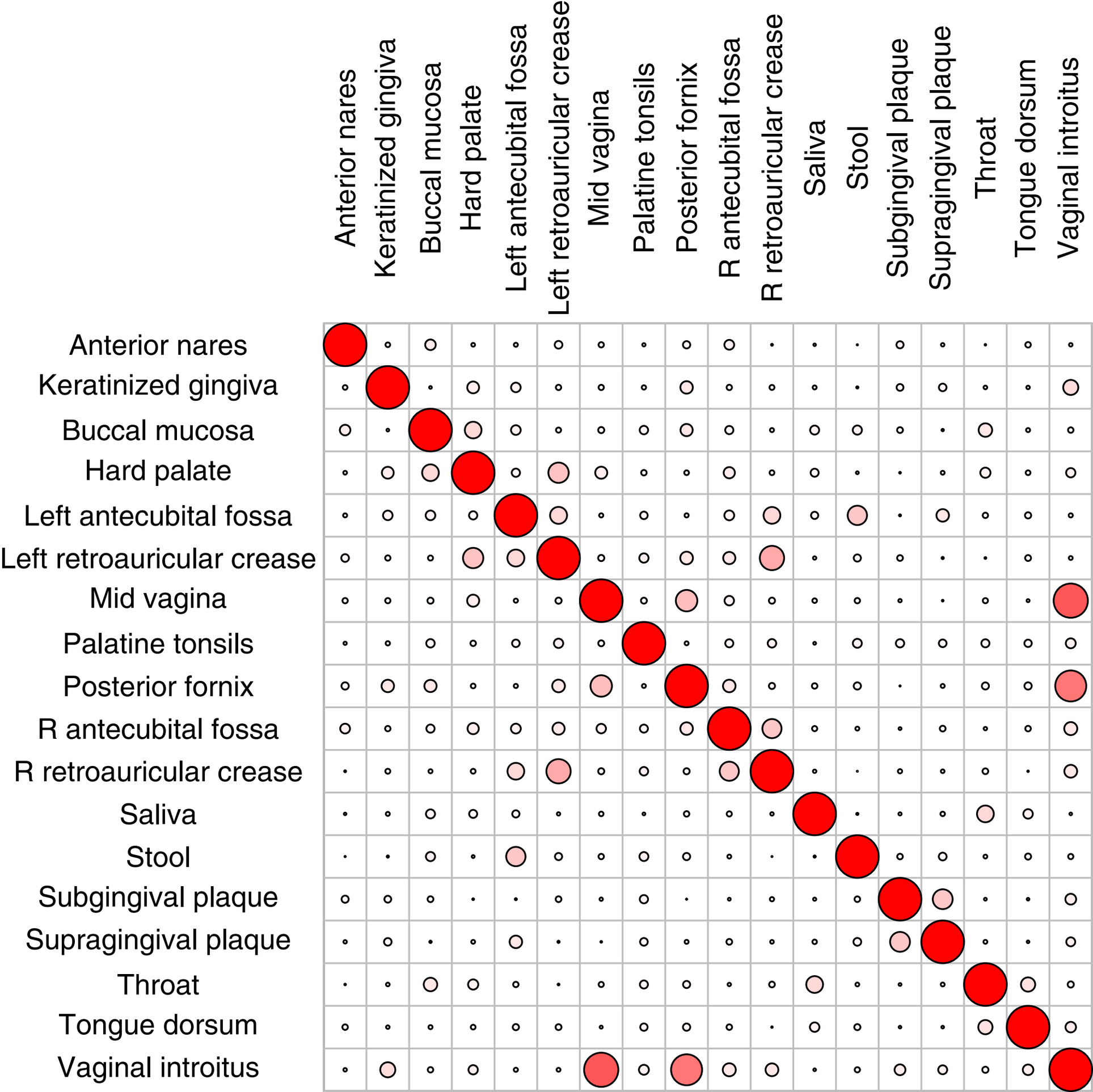
Anterior nares
Keratinized gingiva
Buccal mucosa
Hard palate
Left antecubital fossa
Left retroauricular crease
Mid vagina
Palatine tonsils
Posterior fornix
R antecubital fossa
R retroauricular crease
Saliva
Stool
Subgingival plaque
Supragingival plaque
Throat
Tongue dorsum
Vaginal introitus